



## Primary breast angiosarcoma in postmenopausal women with a picture like Kasabach-Merritt syndrome – A case report

Primarni angiosarkom dojke kod žene u postmenopauzi sa slikom nalik na Kasabach-Merritt-ov sindrom

Mirjana Ćuk\*<sup>†</sup>, Radoslav Gajanin\*<sup>§</sup>, Radmil Marić\*<sup>†</sup>, Veljko Marić\*<sup>†</sup>,  
Svjetlana Todorović\*, Milena Vasić Milanović<sup>1</sup>

\*University of East Sarajevo, Faculty of Medicine, Foča, Republic of Srpska, Bosnia and Herzegovina; <sup>†</sup>University Hospital, Center for Laboratory Diagnosis, Foča, Republic of Srpska, Bosnia and Herzegovina; <sup>‡</sup>University of Banja Luka, Faculty of Medicine, Banja Luka, Republic of Srpska, Bosnia and Herzegovina; <sup>§</sup>University Clinical Center, Department of Pathology, Banja Luka, Republic of Srpska, Bosnia and Herzegovina; <sup>1</sup>Public Health Hospital, Zvornik, Republic of Srpska, Bosnia and Herzegovina

### Abstract

**Introduction.** Primary angiosarcoma of the breast (PAB) is a very rare tumor and accounts for 0.04% of all breast malignant tumors and most commonly occurs in young women. Kasabach-Merritt syndrome (KMS) is described as consumption coagulopathy with thrombocytopenia, and without adequate therapy almost certainly leads to a very fast lethal outcome. The literature contains only a few cases of PAB associated with thrombocytopenia or with KMS and there are no clear defined protocols for the treatment of these patients, which requires the presentation of as many cases as possible. **Case report.** We presented a rare case of 60-year-old postmenopausal woman with metastatic PAB grade III associated with a picture like KMS (thrombocytopenia and anemia without the coagulation factor disorder with massive bleeding in the tumor). Mastectomy was performed without the extirpation of the axillary region. After the surgery, improvement with anemia and thrombocytopenia was noticed. One month after the surgery, supportive and

symptomatic therapy was administered, as well as bisphosphonate therapy, but with temporary improvement. Deplasmated erythrocytes and methylprednisolone were added during the another hospital stay, but prominent symptoms of general weakness along with the progression of thrombocytopenia were noted. Fibrinogen and coagulation factors were within reference values all the time. The patient died four months after the surgery. **Conclusion.** PAB in postmenopausal women is a very rare tumor, and may be associated with anemia and thrombocytopenia without other laboratory parameters for KMS. Anemia and thrombocytopenia are refractory to standard treatment protocols, and also significantly reduces the quality of life of these patients.

### Key words:

angiosarcoma of the breast; breast neoplasms; diagnosis; histological techniques; immunohistochemistry; kasabach-merritt syndrome; postmenopause; thrombocytopenia; treatment outcome.

### Apstrakt

**Uvod.** Primarni angiosarkom dojke je vrlo redak tumor koji čini 0,04% svih malignih tumora dojke, a najčešće se javlja kod mladih žena. Kasabach-Merritt-ov sindrom (KMS) je opisan kao potrošna koagulopatija sa trombocitopenijom i bez adekvatne terapije gotovo sigurno dovodi do veoma brzog letalnog ishoda. Literatura sadrži samo nekoliko slučajeva primarnog angiosarkoma dojke povezanih sa trombocitopenijom ili sa KMS-om i nema jasno definisanih protokola za lečenje tih bolesnika, što zahteva prezentaciju što većeg broja slučajeva.

**Prikaz bolesnika.** Prikazali smo redak slučaj žene u postmenopauzi, starosti 60 godina, sa metastatskim primarnim angiosarkomom desne dojke trećeg stepena udruženim sa slikom sličnom KMS (trombocitopenija i anemija bez poremećaja faktora koagulacije, sa masivnim krvarenjem u tumoru). Urađena je mastektomija, bez odstranjivanja aksilarne regije. Posle hirurške intervencije došlo je do poboljšanja, ali su registrovani anemija i trombocitopenija. Mesec dana posle hirurške ordinirana je suportivna i simptomatska terapija, kao i terapija bifosfonatima, ali sa privremenim poboljšanjem. Terapiji su dodati deplazmatisani eritrociti i

metilprednizolon tokom ponovnog hospitalnog lečenja, ali je došlo do izraženih simptoma opšte slabosti zajedno sa registrovanom progresijom trombocitopenije. Fibrinogen i faktori koagulacije su sve vreme bili u okviru referentnih vrednosti. Bolesnica je umrla četiri meseca posle hirurške intervencije. **Zaključak.** Primarni angiosarkom dojke kod žena u postmenopauzi je vrlo redak tumor i može biti povezan sa anemijom i trombocitopenijom bez drugih laboratorijskih parametara

tipičnih za KMS. Anemija i trombocitopenija su otporne na standardne protokole lečenja, a takođe značajno smanjuju kvalitet života tih bolesnika.

#### Ključne reči:

**dojka, angiosarkom; dojka, neoplazme; dijagnoza; histološke tehnike; imunohistohemija; kasabach-merritt sindrom; postmenopauza; trombocitopenija; lečenje, ishod.**

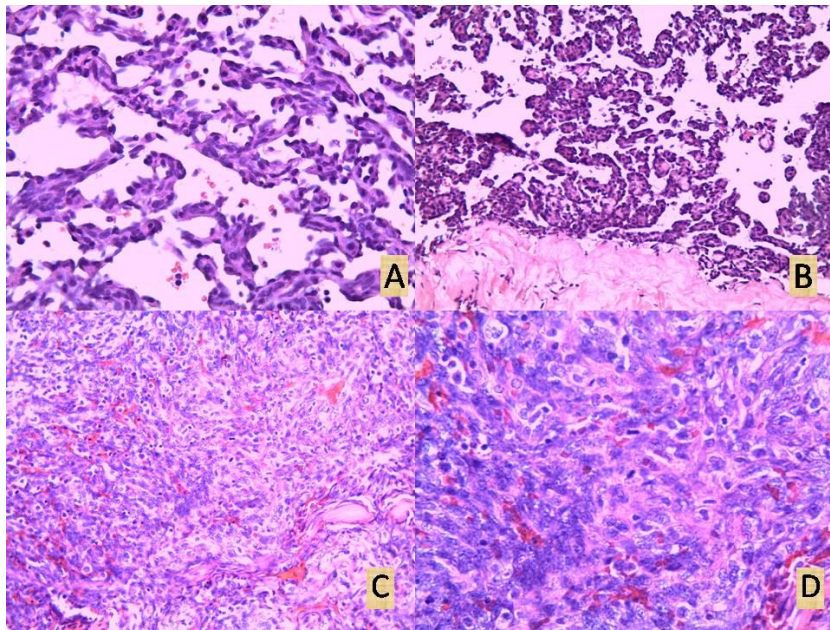
### Introduction

Primary angiosarcoma of the breast (PAB) is a very rare, soft tissue tumor, and makes less than 0.04% of all malignant breast tumors and about 1% of all soft tissue breast tumors<sup>1</sup>. The etiology of this tumor is unknown. It usually occurs in the third and fourth decade of life as opposed to other malignant tumors of the breast<sup>2</sup>. Secondary angiosarcoma of the breast is more likely to occur in elderly women patients as a result of previous radiotherapy and mastectomy<sup>3</sup>. Kasabach-Merritt syndrome (KMS) is described as consumption coagulopathy with thrombocytopenia, first detected in children with benign tumors of vascular genesis, and recently has also been described in adults usually in association with malignant tumors of vascular genesis<sup>4</sup>.

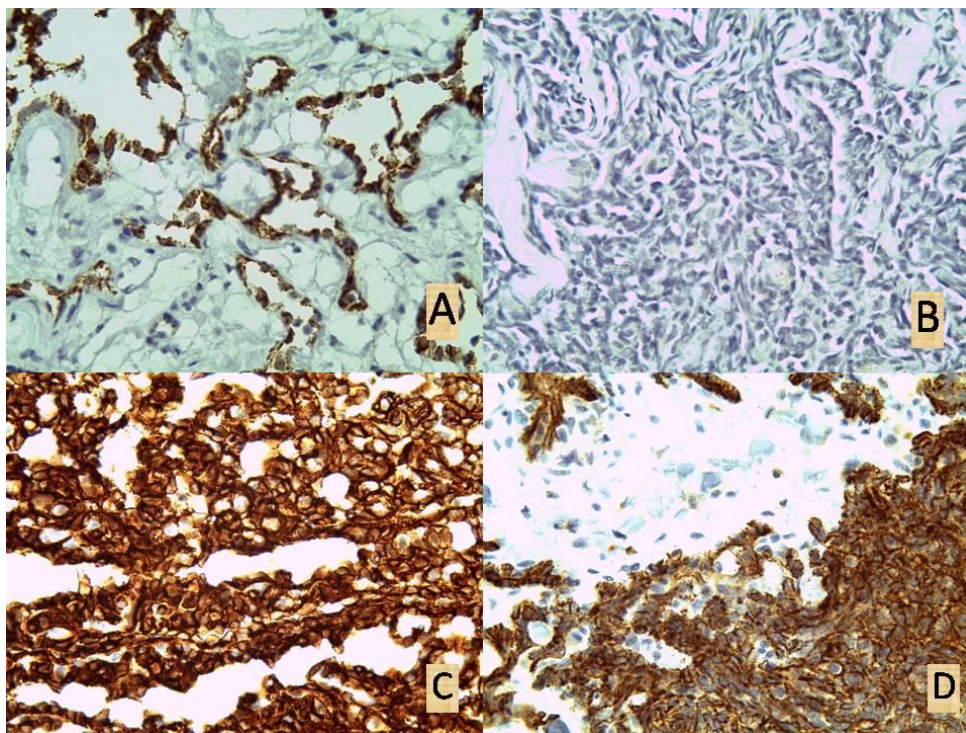
### Case report

We presented a 60-year-old postmenopausal woman who was admitted to our hospital because of the pain in the lumbar region of the spine. Eighteen months ago, the patient noticed swelling and induration in the right breast, without pain and without nipple discharge from. Previous surgical procedures and radiation were denied. When examining the right breast, it was enlarged, occupied by a tumor mass of the largest diameter of 15 cm with the presence of fluctuations in the tumor. The skin of the breast above the tumor was livid and tense. Physical findings in the left breast and both axillary regions were neat. In laboratory findings, accelerated sedimentation of 50/87 values was noticeable, elevated values of lactate dehydrogenase (LDH) – 303 U/L (normal values less than 241 U/L) as well as moderate anemia and mild thrombocytopenia: white blood cells (WBC) –  $4.6 \times 10^9/L$  [reference range (rr)  $4.5\text{--}11 \times 10^9/L$ ]; red blood cells (RBC) –  $3.14 \times 10^{12}/L$  (rr  $4.1\text{--}5.1 \times 10^{12}/L$ ); haemoglobin (Hgb) – 88 g/L (rr 120–160 g/L); hematocrit (Hct) – 0.27 (rr 0.356–0.470); platelets (PLT) –  $122 \times 10^9/L$  (rr  $150\text{--}400 \times 10^9/L$ ). Other laboratory findings were within the limits of the reference values: fibrinogen – 7.2  $\mu\text{mol}/L$  (rr 5.9–11.7  $\mu\text{mol}/L$ ); coagulation time – 430 sec (rr 10–18 min); bleeding time – 110 sec; prothrombin time – 12 sec (rr  $12.3 \pm 0.18$  sec); prothrombin index – 100% (rr 70%–130%); international normalized ratio (INR) – 1 (rr 0.9–1.2); aspartate aminotransferase (AST) – 19 U/L (rr 8–43 U/L); alanine aminotransferase (ALT) – 18 U/L (rr 7–55 U/L); creatinine – 111  $\mu\text{mol}/L$  (rr 60–110  $\mu\text{mol}/L$ ); urea – 6.2 mmol/L (rr 2.9–8.2 mmol/L); glucose – 4.95 mmol/L (normal values less than 5.6 mol/L);

cholesterol – 4.85 mmol/L (rr 3.5–5 mmol/L); triglyceride – 1.61 mmol/L (normal values less than 1.7 mmol/L); electrolytes ( $\text{Na}^+$  – 143 mmol/L (rr 135–145 mmol/L);  $\text{K}^+$  – 4.7 mmol/L (rr 3.5–4.5 mmol/L);  $\text{Cl}^-$  – 100 mmol/L (rr 98–108 mmol/L);  $\text{Ca}^{2+}$  – 1.31 mmol/L (rr 2.2–2.5 mmol/L)). Core tumor biopsy resulted in fragments of necrotic detritus and blood. Computed tomography (CT) confirmed metastatic deposits in the lungs, liver, spinal vertebrae and ribs. During hospitalization, the right breast was rapidly enlarged with severe pain and tension of the skin. Because of the skin tear above the tumor, mastectomy was performed without the extirpation of the axillary region. Intraoperatively, rupture of the tumor node occurred with evident abundant central bleeding area. By macroscopic examination, the tumor tissue mostly appeared to be coagulated blood, dilapidated, and only on the periphery underneath the skin there was a narrow area of grayish-white, highly vascularized tumor tissue of firm consistency. A microscopic examination of the tumor tissue recorded a colorful picture. The tumor was composed of solid areas of atypical spindle cells, capillary vessels of irregular shape incorporated in collagen stroma, and focal papillary proliferation of atypical, spindle and polygonal tumor cells with necrosis zones (Figure 1). Mitoses were numerous, more than 80 to 10 high-power fields. Positive immunohistochemical reaction was present on endothelium specific antibodies: CD31, CD34 and factor VIII, and negative on S100. A definitive diagnosis was set: Angiosarcoma of the breast, grade III (Figure 2). Preoperatively and postoperatively, the patient was given two doses of deplasmated erythrocytes. After the surgery, improvement with anemia and thrombocytopenia was noticed: WBC –  $3.3 \times 10^9/L$ ; RBC –  $3.37 \times 10^{12}/L$ ; Hgb – 92 g/L; Hct – 0.28; PLT –  $156 \times 10^9/L$ . This patient was presented to Oncology Advisory Board one month after the surgery with laboratory findings of blood count: WBC –  $3.5 \times 10^9/L$ ; RBC –  $2.74 \times 10^{12}/L$ ; Hgb – 81 g/L; Hct – 0.23; PLT –  $104 \times 10^9/L$ . Supportive and symptomatic therapy was indicated, as well as bisphosphonate therapy. Because of the progressive anemia and thrombocytopenia, the patient was admitted to the hospital again very soon. Deplasmated erythrocytes and methylprednisolone were ordinated. Blood count was as follows: WBC: 3.2 ... 4.4 ... 4.7... 4.4 ... 5.1 ...  $6.2 \times 10^9/L$ ; RBC: 1.84 ... 2.07 ... 2.50 ... 2.64 ... 2.76...  $3.32 \times 10^{12}/L$ ; Hgb: 57 ... 58 ... 74 ... 76 ... 78 ... 95 g/L; Hct: 0.18 ... 0.19 ... 0.23 ... 0.24 ... 0.25 ... 0.31; PLT: 87 ... 89 ... 74 ... 58 ... 64 ...  $67 \times 10^9/L$ . After the improvement of anemia, the patient was sent to home treatment with recommendation to continue with supportive,



**Fig. 1 – Angiosarcoma of the breast: A) area with capillary histopathological picture [hematoxylin and eosin (H&E) stain,  $\times 400$ ]; B) area with papillary histopathological picture (H&E stain,  $\times 200$ ); C) area with a solid histopathological picture (H&E stain,  $\times 200$ ); D) area with a solid histopathological picture (H&E stain,  $\times 400$ ).**



**Fig. 2 – Angiosarcoma of the breast: A) Von Willebrand (F VIII),  $\times 400$ ; B) S 100,  $\times 400$ ; C) CD34,  $\times 400$ ; D) CD31,  $\times 400$ .**

symptomatic and oral corticosteroid therapy. However, the patient visited us again because of the prominent symptoms of general weakness. During the hospitalisation on a daily basis, the patient was given deplasmated erythrocytes and methylprednisolone. The blood count was as follows: WBC:  $5.6 \dots 5.8 \dots 5.0 \dots 5.0 \dots 5.1 \times 10^9/L$ ; RBC:  $1.34 \dots 1.71 \dots$

$1.69 \dots 2.07 \dots 2.09 \times 10^{12}/L$ ; Hgb:  $41 \dots 51 \dots 52 \dots 60 \dots 62 \text{ g/L}$ ; Hct:  $0.13 \dots 0.16 \dots 0.16 \dots 0.19 \dots 0.19$ ; PLT:  $59 \dots 53 \dots 51 \dots 44 \dots 39 \times 10^9/L$ . The improvement with anemia and progression of thrombocytopenia was noticed. Fibrinogen and coagulation factors were still within reference value. The patient died four months after the surgery.

## Discussion

PAB is a very rare tumor and most commonly occurs in young women. Yin et al.<sup>5</sup> have shown that high grade PAB occurs at a significantly younger age compared to intermediate and low grade PAB, 24:35:41, respectively<sup>4</sup>. Diagnosis of PAB is most commonly rapid and accurate thanks to modern imaging techniques, and is confirmed by a definitive histopathological analysis on core biopsy samples. Although the core biopsy has become the gold standard in breast tumor diagnosis, in cases like ours in which over 90% of the tumor mass is necrotic with massive central bleeding, this method is quite limited in obtaining representative samples. The diagnosis of primary angiosarcoma may be challenging even in cases without massive necrosis and bleeding. Differential diagnosis of low grade angiosarcoma includes benign vascular lesions: hemangiomas, papillary endothelial hyperplasia, and diffuse dermal angiomatosis<sup>6,7</sup>. The main differential diagnostic problem in high grade angiosarcoma is sarcomatoid carcinoma. In setting up the diagnosis of sarcomatoid carcinoma, the most important parameter is the negativity of tumor cells to vascular markers, while the cells of the epithelioid subtype of PAB can express cytokeratin receptors on the surface<sup>8</sup>.

Progressive thrombocytopenia in vascular tumors is often a sign of consumption coagulopathy associated with KMS. KMS is characterized by: rapidly enlarging vascular anomaly established, hypofibrinogenaemia, consumption coagulopathy, thrombocytopenia, prolonged prothrombin time

and activated prothrombin time, presence of d-dimer and fibrin split products with or without microangiopathic haemolytic anemia. Management of KMS includes high dose of corticosteroids and interferon alpha. Other therapeutic modalities include compression of the lesion, arterial embolization with bleomycin, laser therapy, sclerotherapy, radiotherapy and chemotherapy with vincristine, doxorubicin, paclitaxel and use of drugs such as pentoxifylline, dipyridamole and propranolol. An unrecognized syndrome, without adequate therapy, almost certainly leads to a very fast lethal outcome<sup>9,10</sup>.

## Conclusion

PAB in postmenopausal women is a very rare tumor, and may be associated with anemia and thrombocytopenia without other laboratory parameters for KMS. Anemia and thrombocytopenia are refractory to standard treatment protocols, and also significantly reduces the quality of life of these patients. The literature contains only a few cases of PAB associated with thrombocytopenia or with KMS and there are no clearly defined protocols for the treatment of these patients, which requires the presentation of as many cases as possible.

## Conflict of interest

The authors have no conflicts of interest to declare.

## R E F E R E N C E S

- Hui A, Henderson M, Speakman D, Skandarajah A. Angiosarcoma of the breast: a difficult surgical challenge. *Breast* 2012; 21(4): 584–9.
- Torres KE, Ravi V, Kin K, Yi M, Guadagnolo BA, May CD, et al. Long-term outcomes in patients with radiation-associated angiosarcomas of the breast following surgery and radiotherapy for breast cancer. *Ann Surg Oncol* 2013; 20(4): 1267–74.
- Seinen JM, Styring E, Verstappen V, Vult von Steyern F, Rydholm A, Suurmeijer AJ, et al. Radiation-associated angiosarcoma after breast cancer: high recurrence rate and poor survival despite surgical treatment with R0 resection. *Ann Surg Oncol* 2012; 19(8): 2700–6.
- O'Rafferty C, O'Regan GM, Irvine AD, Smith OP. Recent advances in the pathobiology and management of Kasabach-Merritt phenomenon. *Br J Haematol* 2015; 171(1): 38–51.
- Yin M, Wang W, Drabick JJ, Harold HA. Prognosis and treatment of non-metastatic primary and secondary breast angiosarcoma: a comparative study. *BMC Cancer* 2017; 17(1): 295.
- Guilbert MC, Frost EP, Brock JE, Lester SC. Distinguishing papillary endothelial hyperplasia and angiosarcoma on core needle biopsy of the breast: The importance of clinical and radiologic correlation. *Breast J* 2018; 24(4): 487–92.
- Brodie C, Provenzano E. Vascular proliferations of the breast. *Histopathology* 2008; 52(1): 30–44.
- Cunha AL, Amendoeira I. High-Grade Breast Epithelioid Angiosarcoma Secondary to Radiotherapy Metastasizing to the Contralateral Lymph Node: Unusual Presentation and Potential Pitfall. *Breast Care (Basel)* 2011; 6(3): 227–9.
- Wang P, Zhou W, Tao L, Zhao N, Chen XW. Clinical analysis of Kasabach-Merritt syndrome in 17 neonates. *BMC Pediatr* 2014; 14: 146.
- Arunachalam P, Kumar VR, Swathi D. Kasabach-Merritt syndrome with large cutaneous vascular tumors. *J Indian Assoc Pediatr Surg* 2012; 17(1): 33–6.

Received on September 14, 2018.

Revised on May 5, 2019.

Accepted June 10, 2019.

Online First June, 2019.